

CASE REPORT**Complex Odontoma: Early Detection, Immediate Correction**

Ashwini Rani^{1*}, Jaishankar², Shashidara², Girish Suragimath³

¹Department of Oral Medicine and Radiology, ²Department of Periodontology, School of Dental Sciences, Krishna Institute of Medical Sciences Deemed University, Karad - 415539, (Maharashtra), India, ³Department of Oral Medicine and Radiology Coorg Institute of Dental Sciences, Virajpet - 571218, Madikeri district, (Karnataka), India.

Abstract:

Odontomas are the most common odontogenic tumours of the jaws, which are benign, slow growing and nonaggressive. Odontomas are usually asymptomatic, but sometimes may interfere with the eruption of the associated teeth leading to impaction or delayed eruption and displacement of adjacent teeth resulting in malocclusion. This article presents a case of complex odontoma in a 12-year-old male patient, who reported with a complaint of delayed eruption of permanent left maxillary first and second molars. The radiological features revealed impacted first, second and third molars with a radiolucent capsule and a corticated border suggestive of Odontoma. A treatment of surgical excision of the lesion, followed by orthodontic traction of unerupted maxillary left first and second molars was carried out successfully. The patient was followed for two years with no recurrence of the lesion.

Keywords: Complex type, Compound type, Hamartomas, Odontoma.

Introduction:

Odontomas are considered developmental anomalies resulting from the growth of completely differentiated epithelial and mesenchymal cells that give rise to ameloblasts and odontoblasts. There are two types of odontomas, complex and compound type, depending on the resemblance to the anatomic tooth. Compound odontomas are usually located in the anterior region of maxilla, whereas complex odontomas are found in the posterior mandibular region over impacted teeth. Odontomas may be diagnosed at any age but they are usually detected during the

first two decades of life. The diagnosis is usually established on routine radiographic investigations. Odontomas are often seen in permanent dentition and are rarely associated with primary teeth [1]. This article presents a case of complex odontoma in a 12-year-old male patient, treated by surgical excision of the lesion, and orthodontic correction of impacted teeth.

Case Report:

A 12-year-old male patient reported to the Department of Oral Medicine and Radiology, with a complaint of delayed eruption of his upper left back teeth. Extraoral examination showed no facial asymmetry, intraorally maxillary left first and second molars were clinically missing and on palpation, a hard mass was felt in that region (Fig.1). Provisional diagnosis of dentigerous cyst with a differential diagnosis of odontoma was considered.

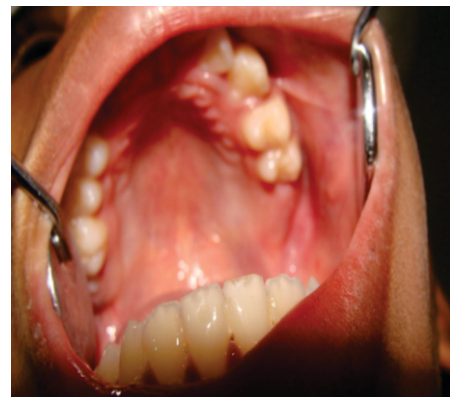

Fig. 1: Intraoral Photograph of Maxillary Left Quadrant with Clinically Missing Molars

Radiographic examination with periapical radiograph revealed erupted maxillary left second premolar with incomplete root formation and open apex, impacted first and second molars and tooth crypt of third molar. Multiple radiopacities were observed on the occlusal surface of first and second molars, with the density similar to that of enamel. A radiolucent capsule and a well-defined outer cortical border surrounded the entire area (Fig. 2).

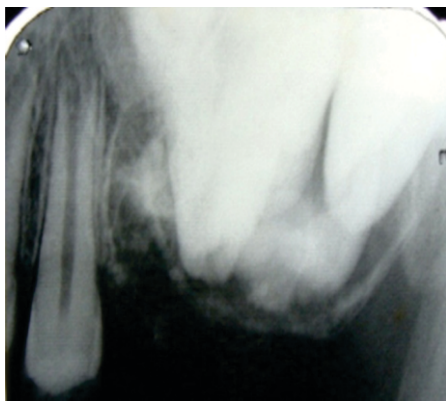


Fig. 2: Peri Apical Radiograph Showing Impacted First, Second Molars and Tooth Crypt of Third Molar with Multiple Radiopacities on the Occlusal Surfaces

Orthopantomogram showed impacted maxillary left first, second and third molars with multiple radiopacities on the occlusal surfaces (Fig. 3).

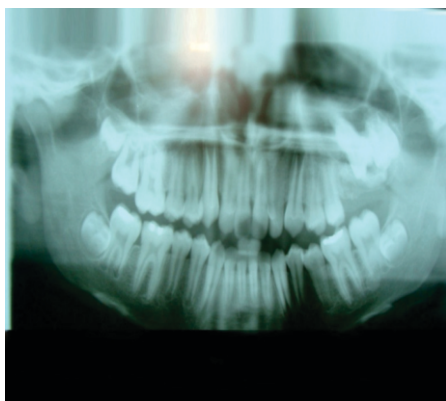


Fig. 3: Orthopantomogram Showing Impacted Maxillary Left First, Second and Third Molars.

Based on radiographic findings a diagnosis of odontoma was arrived. Treatment of surgical excision of the lesion with extraction of tooth crypt of third molar and, orthodontic traction of left maxillary first and second molars was planned and carried out (Fig. 4).

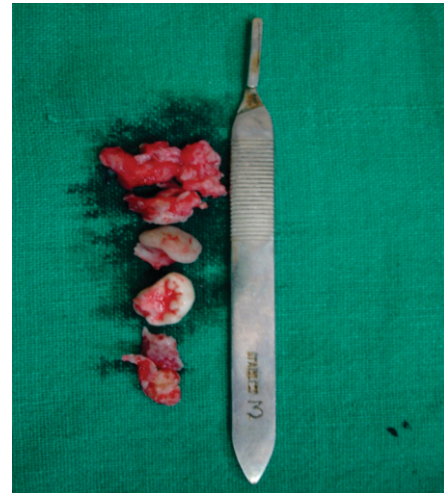

Fig. 4: Surgically Excised Pathological Tissues with Extracted Third Molar

The excised tissue under H & E stained section, showed calcified areas resembling dentin with areas of globular calcifications, and entrapped pulp tissue with occasional foci of odontogenic epithelium and mesenchymal connective tissue stroma. Overall features were consistent with complex odontoma (Fig. 5 and 6).

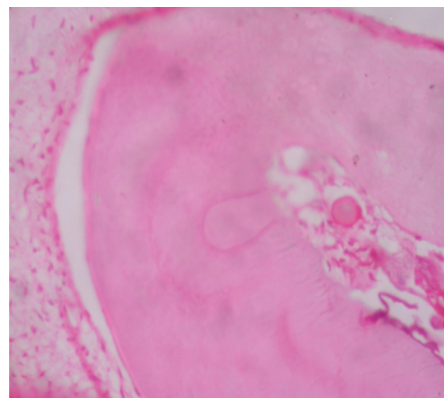


Fig. 5: 10X, H & E Stained Section

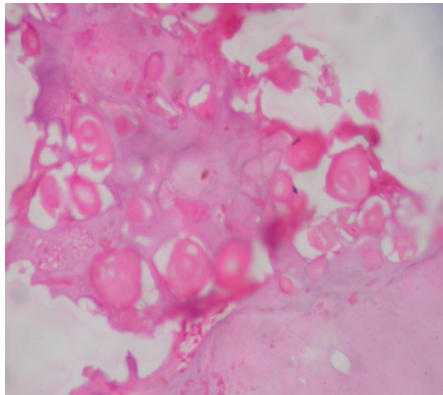


Fig. 6: 40X, H & E Stained Section Showing Calcified Areas Resembling Dentin with Areas of Globular Calcifications and Entrapped Pulp Tissue with Occasional Foci of Odontogenic Epithelium and Mesenchymal Tissue

Based on the clinical, radiographic and histopathological examination, a final diagnosis of Complex odontoma was concluded. The impacted first and second molars were brought into occlusion orthodontically, and followed up for two years with no recurrence of odontoma (Fig. 7).

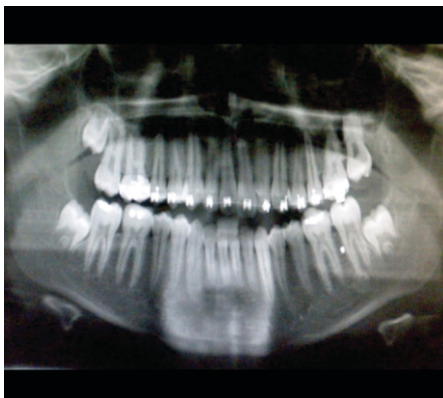


Fig. 7: Follow Up Orthopantomogram Showing Left Maxillary First Molar in Occlusion

Discussion:

The term “odontome” was first coined by Paul Broca in 1867 to designate all tumours of odontogenic origin. In 1946, Thoma and Goldman developed a classification limiting the use of the

term odontome to lesions composed of tooth like structures. The complex composite type is a hamartomatous lesion in which all the dental tissues are represented, individual hard tissues being mainly well formed but occurring in a more or less disorderly pattern. Complex types are slow growing, expanding lesions that are usually detected in the second decade. According to Kaugars and colleagues 54% of cases were found in the second decade of life and only 15% in patients older than 30 years. In our case, the patient was in the second decade. The exact etiology of odontomas is uncertain, local trauma, infection, growth pressure, hereditary and developmental influences have been suggested as possible causes [2].

Odontomas are usually asymptomatic lesions and in most cases, they are associated with alterations in tooth eruption temporarily or permanently. The incidence of this association ranges from 41% according to Katz [3] and 87% according to Tomizawa et al [4]. In our case patient presented with delayed eruption of maxillary left first and second molars. Impaction or altered eruption occurs because the odontoma obstructs the eruptive trajectory of the teeth. Radiographically three different developmental stages can be identified depending on the degree of calcification of odontoma. In the first stage the lesion appears radiolucent due to the lack of calcification, intermediate stage is characterized by partial calcification and in the final stage the odontoma appears radio-opaque, which is surrounded by a radiolucent halo [5, 6]. In the present case, impacted maxillary left first and second molars and tooth crypt of third molar were noted, with multiple radiopacities surrounded by a radiolucent capsule and a well defined outer cortical border, suggestive of final stage of odontoma.

Odontomas are generally intrabony lesions, though in exceptional cases the odontoma may spontaneously erupt into the oral cavity. The first case of an erupted odontoma was described in 1980 by Rumel et al [7] and since then only 17 cases have been documented in the English language literature till date. The treatment of choice for these impacted teeth associated with odontomas appears to be removal of the lesion with preservation of the impacted tooth, which was carried out in our case. The latter in turn require clinical and radiological follow-up for at least one year [8-10]. If no changes in the position of the tooth are seen during this period, fenestration followed by orthodontic traction is indicated. Surgical treatment of odontoma is conservative and curative with no possibility of recurrence, if the lining epithelium is removed intact. But one case of recurrent odontoma has been reported and

the reasons stated for recurrence include –

- 1) Repeated episodes of infection in same region
 - 2) Multiple schizodontia due to dental lamina activity
 - 3) Odontogenic rests left behind [11].
- In the present case surgical excision of the lesion followed by orthodontic traction for correction of malocclusion was carried out. Patient follow up was conducted for one year until maxillary left first and second molars were orthodontically aligned and no recurrence of the lesion was observed.

Conclusion:

Odontomas are asymptomatic lesions, which go undiagnosed until serious developmental and craniofacial complications occur. Routine use of panoramic radiography is advocated for early detection and proper management of odontomas.

References:

1. Sharma U, Sharma R, Gulati A, Yadav R, Gauba K. Compound composite odontoma with unusual number of denticles –A rare entity. *Saudi Dent J* 2010; 22 (3):145-149.
2. Hitchin AD. The etiology of calcified composite odontomes. *Br Dent J* 1971; 130:475-482.
3. Katz R. An analysis of compound and complex odontomas. *ASDC J Dent Child* 1989; 56(6): 445-449.
4. Tomizawa M, Otsuka Y, Noda T. Clinical observations of odontomas in Japanese children: 39 cases including one recurrent case. *Int J Paediatr Dent* 2005; 15(1): 37-43.
5. Vengal M, Arora H, Ghosh S, Pai KM. Large erupting complex odontoma: A case report. *J Can Dent Assoc* 2007; 73(2):169-173.
6. Amado Cuesta S, Gargallo Albial J, Berini Aytés L, Gay Escoda C. Review of 61 cases of odontoma. Presentation of an erupted complex odontoma. *Med Oral* 2003; 8(5):366-373.
7. Rumel A, de Fritas A, Birman E, Tannous L, Chacon P, Borkas S. Erupted complex odontoma. Report of a case. *Dentomaxillofac Radiol* 1980; 9(1): 5-9.
8. Kulkarni VK, Vanka A, Shashikiran ND. Compound odontoma associated with an unerupted rotated and dilacerated maxillary central incisor. *Contemp Clin Dent* 2011; 2(3): 218-221.
9. Nagaraj K, Upadhyay M, Yadav S. Impacted maxillary central incisor, canine, and second molar with 2 supernumerary teeth and an odontoma. *Am J Orthod Dentofacial Orthop* 2009; 135: 390-399.
10. Serra-Serra G, Berini-Aytés L, Gay-Escoda C. Erupted odontomas: a report of three cases and review of the literature. *Med Oral Patol Oral Cir Bucal* 2009; 14(6): 299-303.
11. Pande S, Ganvir SM, Hazarey VK. Recurrent Odontome- A rarity. *J Indian Dent Assoc* 2003; 74: 115-118.

*Author for Correspondence: Dr. Ashwini Rani, Senior Lecturer, Department of Oral Medicine and Radiology, School of Dental Sciences, KIMSUDU, Malkapur - 415539 Maharashtra, India.
Cell: 7798250369, 8007467216 E-Mail: drashwiniranisr@yahoo.in, drashwiniranisr@gmail.com